

---

## Disease conditions and subclinical infections of the platypus (*Ornithorhynchus anatinus*)

B. L. Munday, R. J. Whittington and N. J. Stewart

*Phil. Trans. R. Soc. Lond. B* 1998 **353**, 1093-1099  
doi: 10.1098/rstb.1998.0268

---

### Email alerting service

Receive free email alerts when new articles cite this article - sign up in the box at the top right-hand corner of the article or click [here](#)

---

To subscribe to *Phil. Trans. R. Soc. Lond. B* go to: <http://rstb.royalsocietypublishing.org/subscriptions>

---



# Disease conditions and subclinical infections of the platypus (*Ornithorhynchus anatinus*)

B. L. Munday<sup>1</sup>, R. J. Whittington<sup>2</sup> and N. J. Stewart<sup>1</sup>

<sup>1</sup>Department of Aquaculture, University of Tasmania, PO Box 1214, Launceston, Tasmania 7250, Australia

<sup>2</sup>Elizabeth Macarthur Agricultural Institute, PMB 8, Camden, New South Wales 2570, Australia

Before the arrival of European settlers in Australia, the platypus, *Ornithorhynchus anatinus*, probably suffered from little disease. Among other things, European settlement has involved substantial environmental perturbation, introduction of large predators, introduction of motor vehicles and translocation of potential pathogens. As a result, platypuses are now killed by motor vehicles, dogs, foxes and discarded plastic litter. Information programmes targeting appropriate segments of the public would help reduce these unnecessary deaths. The enigmatic disease, ulcerative mycosis, caused by *Mucor amphibiorum*, has been the subject of scientific investigation in Tasmania for the past 15 years. The apparent recent acceleration in its spread has sounded a warning and more intensive investigation is warranted. The possibility that this pathogen has been translocated from subtropical to temperate Tasmania, Australia, with green tree frogs in banana shipments further emphasizes the role of humans in threatening the welfare of the platypus. Recommendations are made in relation to appropriate measures that could be taken to ameliorate disease and trauma in this species.

**Keywords:** platypus; *Ornithorhynchus anatinus*; disease; infection

## 1. INTRODUCTION

In recent years, interest in diseases of Australian wildlife has been high and, until the recent depredations of economic rationalism, much good work was undertaken by government and university scientists. However, although this research activity has identified a range of diseases in many Australian species, the list for platypus has remained remarkably short, especially when anthropogenic causes are deleted.

This review provides an overview of the available information and examines in some depth the enigmatic condition, ulcerative mycosis, known to affect platypuses in northern Tasmania, but nowhere else in Australia.

Disease conditions will be discussed under the groupings of pathophysiology, trauma, drowning, predation, infectious diseases and miscellaneous conditions.

## 2. PATHOPHYSIOLOGY

Pathophysiology encompasses abnormalities of physiology leading to overt disease and includes severe stress, starvation, hyperthermia and hypothermia.

It is well recognized that platypuses readily succumb to stress and this has been well documented by Whittington (1988, 1991). Most observations relate to animals in captivity, and although the animals appear to readily withstand up to 24 h confinement, only a proportion of captive platypuses survive longer periods in captivity.

The clinical signs of stress in platypus usually include inappetence with hyperactivity or depression. Hyperactive animals attempt to dig out of their transport box or enclosure often resulting in abrasions on the bill and feet.

Abnormal behaviour in the display tank or burrow system, for example moving bedding material from one nesting chamber to another, has also been recorded, and in some instances abnormal, frenetic feeding activities have been observed (N. Mooney, personal communication). Depressed platypuses do not dry themselves after leaving the water, so that the nest becomes wet; they may be found lying quietly in the tunnel system or nest and do not respond to stimulation. Animals with these clinical signs have often died within several days. Less florid cases of stress may only show listlessness and weight loss, and therefore regular weighing is an important husbandry procedure with captive platypus.

Confirmation that this syndrome is actually mediated by adrenocortical activity is difficult to find. McColl (1983) reported a direct relationship between time in captivity and the adrenal-to-body weight ratio, and there have been some reports of raised glucocorticoid levels in animals that have been presumed to be under stress. McDonald *et al.* (1992) demonstrated that the adrenal response in netted platypuses was very large and its control was similar to most other mammals. Probably as a direct result of this response, peripheral blood lymphocyte counts fall rapidly after capture in most platypuses (Whittington & Grant 1995).

This propensity for platypuses to become stressed in captivity, together with the difficulty of procuring suitable food and general husbandry complexities, explains why they are not regularly kept in zoos and wildlife parks and are infrequently kept for long-term scientific study. Measures that have been taken to ameliorate stress in captive animals include exposing them as exhibits in 'shifts', providing artificial burrows mimicking those

found in nature and protecting the animals from extraneous electrical activity by the use of a Faraday cage (Manger & Pettigrew 1995).

Juvenile platypuses disperse during summer/autumn and may die of starvation because they do not establish a home range with a suitable food supply. Such animals are very thin and weak and are frequently collected by members of the public, often a long distance from their normal habitat during daylight hours. By the time they are found, most of these animals are beyond rehabilitation using standard practices of provision of food and shelter. Obviously, their condition will be exacerbated by the fact that they have been taken into captivity and thereby further stressed.

The normal body temperature of the platypus is 32 °C (Grant 1983) and, even though they have abundant sweat glands, they readily become overheated and may die of hyperthermia if left in traps in direct sunlight or kept in hot rooms or vehicles. At the other extreme, although these animals inhabit many alpine and subalpine waters, it has been suggested that they can suffer from hypothermia, if recently captured and kept in moist, cold conditions. This is especially the case if the animals are in poor condition and/or have been anaesthetized. In such circumstances they readily respond to dry heat if they are still conscious and not excessively stressed (S. Munks, personal communication; B. L. Munday and N. J. Stewart, unpublished data).

### 3. TRAUMA

Many platypuses die as a result of being run over by motor vehicles. Their shape ensures that they are actually run over and they do not move quickly enough to evade motor vehicles. As reported by Tyson (1980), most of these animals are found in the vicinity of road culverts and it has been suggested that, unless the opening of the under-road pipe and the adjacent ground/stream bed are on the same level, the animals are unwilling to use the pipe and instead travel overland. This is not an unusual action as the authors have observed platypuses taking 'short cuts' overland rather than following meandering canals. However, in some instances this explanation is too simplistic and other factors must be involved (N. Mooney, personal communication).

There is evidence that some platypuses are shot, but as this is an illegal activity reliable data are difficult to obtain. Platypuses may also enter power plant intakes and water pipes in dams and streams and be traumatized as a result. R. Booth (personal communication) reported that in two streams near Healesville in Victoria, 10% of platypuses had wounds caused by ring-type litter such as rubber rings, loops of fishing line and off-cuts of plastic pipe. Similar observations have also been made in Tasmania (N. Mooney, personal communication).

### 4. DROWNING

Most drownings are due to misadventure when platypuses are entangled in weighted gill nets set for fish or caught in fyke nets set for eels. Fortunately, few are now caught in fyke nets set by commercial fishers because of modifications incorporated to exclude them. However, illegal use of gill

nets by private citizens and legal use by scientists unaware of the danger to platypuses still cause unnecessary mortalities (P. R. Manger, personal communication).

### 5. PREDATION

Dogs and foxes frequently kill platypus, especially when they are travelling overland between streams or dams. There are usually few external signs of the attack and the extensive puncture wounds are not revealed until necropsy. There has been a report of predation by Tasmanian devils in a partly empty dam (N. Mooney, personal communication).

Richards (1986) reported predation of a juvenile platypus by a goshawk and Mooney (personal communication) has observed a white-bellied sea eagle carrying a platypus. However, the authors are unaware of significant predation by raptors.

### 6. INFECTIOUS DISEASES

Only a limited number of infectious diseases have been reported affecting platypuses and of these only ulcerative mycosis is of significance (Whittington 1992).

#### (a) *Viral diseases*

Two viral diseases have been recognized in platypuses and both produce only minor lesions. Whittington *et al.* (1990) reported subclinical adenovirus-like infection of the kidneys, which induced cytomegalic inclusion disease. The early events in this infection in the platypus are unknown; however, the virus eventually localizes in the epithelial cells of renal collecting ducts. Infected cells undergo startling enlargement as viral replication proceeds. The cell nucleus enlarges, chromatin dissolves and/or marginates, and a large eosinophilic inclusion body appears. Viral particles bud from the cell membrane and accumulate in the tubular lumen adjacent to the membrane. The infected cell finally enlarges to about four times normal size and is shed into the urine. Infected cells are readily seen by light microscopy in the renal medulla. Although platypuses come into close contact in the burrow, particularly during the nursing period, this viral infection is probably transmitted in water.

Papilloma virus is possibly the cause of papules seen on the webbing of the front feet of platypus in the Healesville region in Victoria (R. Booth, personal communication). Putative diagnosis of papilloma virus was based on histological appearance and weak positive immunohistochemical staining for human papilloma virus. Breaks in the integrity of the epidermis predisposes to papilloma virus infection in other species, and there may be a link between litter-contaminated streams and the prevalence of this condition. Once the first lesions were identified, it became apparent that the prevalence in the Healesville region was quite high. These lesions could be difficult to differentiate grossly from healed ulcerative mycosis (N. J. Stewart and B. L. Munday, unpublished data).

#### (b) *Bacterial diseases*

Some bacterial diseases of platypuses are non-specific and associated with conditions such as aspiration

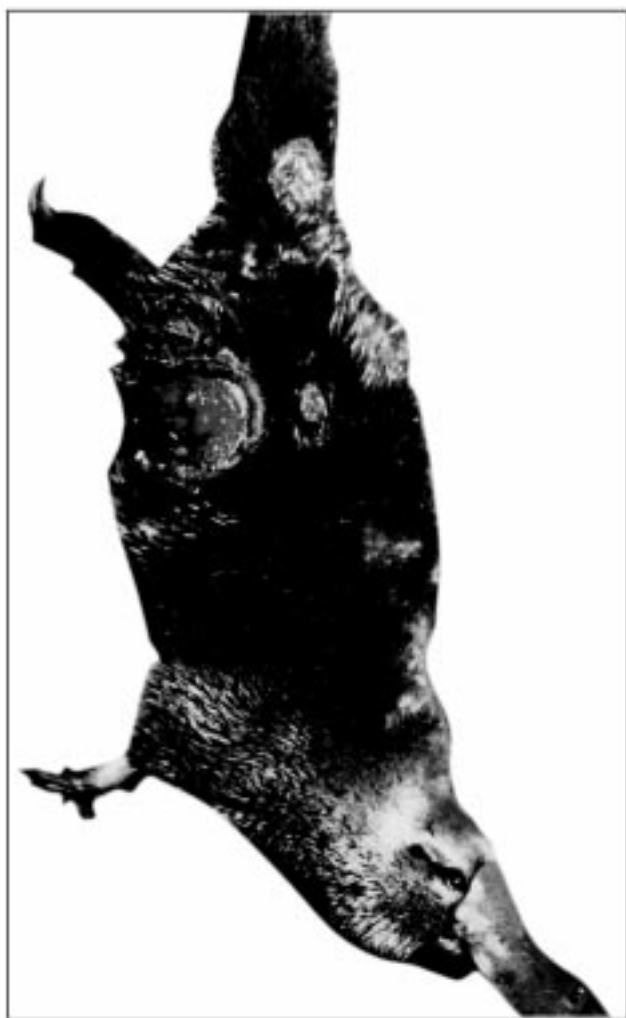

Figure 1. Severely ulcerated platypus.

pneumonia. Others are primary bacterial infections of varying importance.

McCull & Whittington (1985) reported preliminary data indicating that platypuses in New South Wales are infected with one of the antigenic variants, *Leptospira interrogans* serovar *hardjo*. Subsequent serological investigation of 131 platypuses sampled up until 1988 (R. J. Whittington and T. R. Grant, unpublished data) confirmed a prevalence of infection of about 50% in platypuses from the upper Shoalhaven River. Prevalence increased with increasing age, consistent with infection being derived from the environment. In addition, leptospire were demonstrated in silver-stained sections of renal cortex from a platypus drowned in an illegal fishing net, but efforts to isolate the organism in culture have not been successful to date. In general, leptospire are difficult to isolate in artificial culture media. Serological (microscopic agglutination test) titres on *L. hardjo* merely indicate infection with the Hebdomadis serogroup, of which only *L. hardjo* and *L. balcanica* are known in Australia. *L. hardjo* is endemic in cattle and common in sheep, whereas *L. balcanica* is endemic in the brushtail possum. In 1988, R. J. Whittington and K. Hart (unpublished data) demonstrated *L. hardjo* infection in cattle grazing riverbank pasture at the Shoalhaven study area. Cattle had regularly been observed drinking from, and urinating into, the river

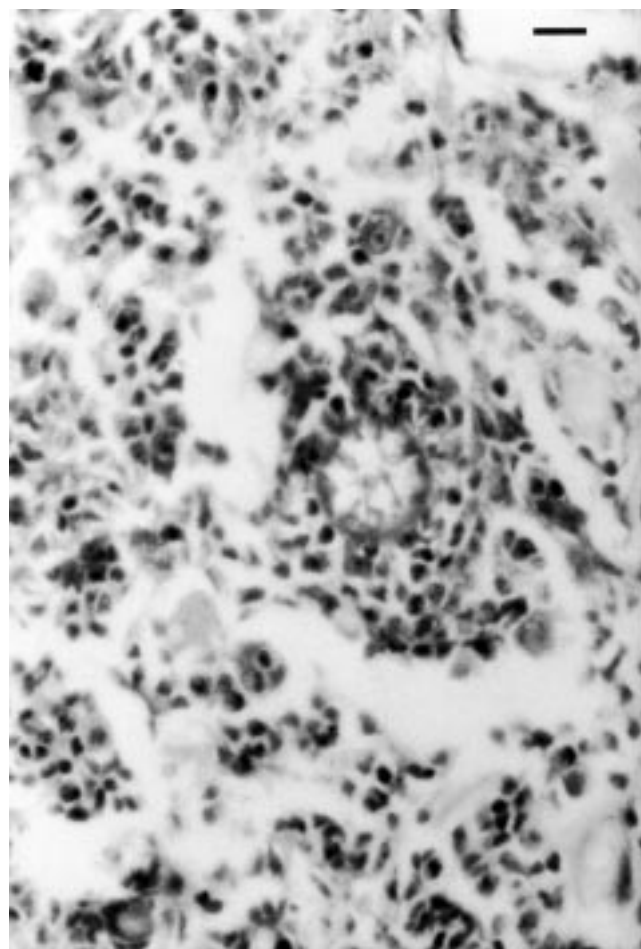


Figure 2. Sphaerule-like form of *M. amphibiorum* in inflamed subcutaneous tissues. Periodic acid-Schiff reaction. Bar, 7.5  $\mu$ m.

at the site. Thus, there was indirect evidence that cattle and platypuses may have been exchanging *L. hardjo* infection. The significance of leptospiral infection in the platypus is not known, but there is no indication that it constitutes any threat to populations.

Salmonellae have been recovered from one wild and two captive platypuses (Whittington 1988). The wild animal, an adult male, was found on a suburban lawn and died, probably of heat stress, within 24 h. Salmonellae were recovered from lung and heart, suggesting that salmonellosis may have caused the animal's unusual behaviour. In captivity, salmonellae were recovered from the faeces of an established animal that had been losing weight. It was treated with Tribissen and excretion of salmonellae ceased. The animal died a year later of septicaemic salmonellosis within three weeks of entering captivity. The animal became hyperactive and developed skin abrasions several days before it was found dead. Apart from subepicardial haemorrhages there were no significant pathological findings. A haemogram on blood collected from the heart post-mortem showed severe lymphopenia. *Salmonella typhimurium* was isolated from faeces.

Whittington & McCull (1983) recovered *Aeromonas hydrophila* and *Escherichia coli* from the lung of a wild animal that died of aspiration pneumonia. The same



mixed flora was recovered from the lung of the animal with septicaemic salmonellosis discussed above. There have been many similar isolates, and because of the ubiquity of these organisms it is difficult to determine whether they are true pathogens, terminal invaders or contaminants. Also, *Pseudomonas aeruginosa* has been associated with otitis externa in captive platypuses (R. Booth, personal communication).

### (c) *Fungal infections*

Two fungal infections have been reported in platypuses. The dermatophyte *Trichophyton mentagrophytes* var. *mentagrophytes* causes alopecia of the tail (Whittington 1992). More significantly, *Mucor amphibiorum* has been identified as the cause of a severe ulcerative dermatitis and pneumonitis of platypuses in northern Tasmania. Clinically, the disease is characterized by single-to-multiple cutaneous ulcers on any part of the body (figure 1), varying in size from 5 to 50 mm in diameter, usually with a rough, greyish, granulating surface and invading the musculature to a depth of 10 mm (Munday & Peel 1983; Obendorf *et al.* 1993). More recently, animals with apparently healing and healed lesions have been seen (N. J. Stewart and B. L. Munday, unpublished data). One platypus with an ulcer on its back had a well-developed scab around the periphery of the lesion, and another with severe ulceration when trapped was sighted three months later with much-reduced lesions. Completely healed lesions, consisting of bulbous scars 3–15 mm in diameter on the feet, have been found in animals captured in the endemic area. When captured six months later, one of these animals had no detectable, residual lesions. Active ulcers cause the animals considerable discomfort and they spend much time scratching and rubbing against objects. Severely ulcerated animals become debilitated and often fly-blown, and mortalities have been recorded as a direct result of this disease.

The microscopic pathology of ulcerative mycosis is characteristic, consisting of a severe, suppurating, caseating, granulomatous dermatitis/myositis associated with the sphaerule-like forms of *M. amphibiorum* (figure 2). Macrophages, fibroblasts and giant cells often predominate in lesions. Healed lesions consist mainly of fibrous tissue with a limited inflammatory component and scant organisms. The lung lesions are those of a granulomatous pneumonitis containing sphaerule-like bodies.

It has been suggested that *M. amphibiorum* infects the platypus, and not other mammals, because of the animal's relatively low body temperature of 32 °C. This is closer to the optimum growth temperature of 30–34 °C for *M. amphibiorum* than is that of other mammals, and is below the maximum temperature permitting growth of six strains tested by Stewart (1996). Interestingly, one isolate from cane toads showed reasonable growth at 38 °C and, therefore, might be capable of infecting other mammals.

Obendorf *et al.* (1993) suggested that the usual means of spread might be through skin wounds. However, the consistent occurrence of lung lesions (Munday & Peel 1983; Obendorf *et al.* 1993; N. J. Stewart and B. L. Munday, unpublished data) raises the question as to whether the initial portal of entry is respiratory, with subsequent dissemination to single or multiple cutaneous sites. The failure to isolate *M. amphibiorum* from the envi-

ronment (Connolly *et al.* 1996), coupled with the high prevalence (*ca.* 30%) of lesions in affected populations (Connolly *et al.* 1996; N. J. Stewart and B. L. Munday, unpublished data), suggests that direct contagion, or at least infection due to recent contamination in burrows, may be responsible for spread of the disease.

Up until 1997 the disease was known only in the catchment area of the River Tamar, a relatively discrete geographic zone with physical barriers on all sides except the northwest (Munday & Peel 1983; Obendorf *et al.* 1993; Connolly *et al.* 1996; N. J. Stewart and B. L. Munday, unpublished data). However, reliable sightings of affected animals to the north-west of the previous endemic zone in 1997 (figure 3) have caused a reassessment of the likely reason(s) for this disease occurring in Tasmanian platypuses and not Queensland platypuses (the latter, presumably, are also exposed to *M. amphibiorum*, which infects cane toads in that State (Speare *et al.* 1994)). This reassessment has also been stimulated by results of preliminary DNA typing with microsatellite loci, which has shown that Tasmanian populations are easily distinguishable from mainland populations (S. Akiyama & N. Murray, personal communication). It is possible that the Queensland platypus has evolved with *M. amphibiorum*, but Tasmanian populations have been isolated from this organism for at least 12 000 years (Galloway & Kemp 1981) and, therefore, are highly susceptible to infection by it.

Our favoured hypothesis for the evolution of this disease in Tasmania is now as follows: *M. amphibiorum* was introduced into Tasmania from Queensland with green tree frogs (*Litoria caerulea*), which are frequently transported from that State around Australia in bunches of bananas (R. Booth, personal communication). These amphibians have been implicated as vectors for this fungus on at least two occasions (Frank *et al.* 1974; Slocombe *et al.* 1995) and are the logical vehicle for its presumed entry into Tasmania. Once established in the vicinity of Campbell Town in the northern midlands of Tasmania, the disease spread along the river systems that compose the tributaries of the River Tamar. This suggestion is supported by personal observations of one of the authors (B. L. Munday) that the disease was not present at its northernmost limit until 1995 and, in addition, by trout fishers who spend long periods each year angling in waters where cases have only been seen in the last two years. Spread has presumably eventually occurred in a westward direction by platypuses travelling overland. Without some form of control or prophylaxis being instituted it is possible that the disease may eventually spread to most populations of platypus in Tasmania with possible severe consequences for relatively isolated communities. There are other tenable hypotheses for the observed distribution of the disease but we do not believe they fit the existing information as well as the one enunciated above.

### (d) *Parasitic infestations*

Only a small number of parasites have been described for the platypus and most do not produce significant pathology. These will be discussed under the groupings of protozoans, cestodes, trematodes, nematodes, insects and arthropods.

*Theileria ornithorhynchi* is present in the peripheral blood of most platypuses (Collins *et al.* 1986) where it parasitizes about 1% of erythrocytes. One-to-four small,

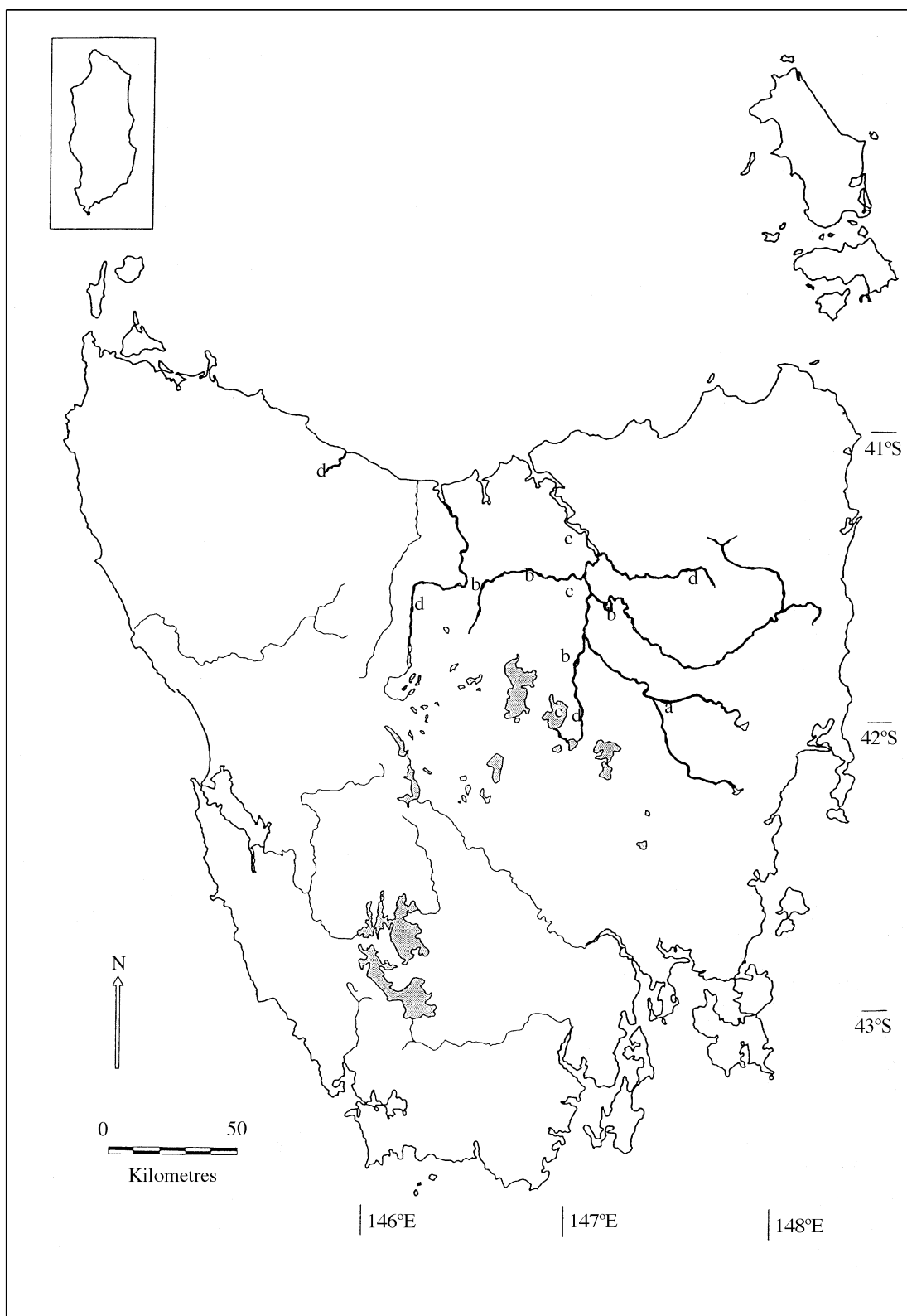


Figure 3. Known distribution of ulcerative mycosis of platypuses in Tasmania: (a) location of index cases in 1982 (Munday & Peel 1983); (b) location of 1992 cases (Obendorf *et al.* 1993); (c) location of 1994/95 cases (Connolly *et al.* 1996); (d) location of 1996/97 cases (N. J. Stewart and B. L. Munday, unpublished data).

round, pear- or comma-shaped bodies, which show polar staining with Romanowsky stains, are found in affected cells. Leucocytes containing large basophilic, intracytoplasmic Koch's bodies are present in the peripheral blood but may be hard to find. Small piroplasms similar to those found in erythrocytes may also be found in leucocytes (Whittington 1988). This parasite is usually regarded as

innocuous but an emaciated, wild juvenile with 12% erythrocytes infected was noted to have a haemolytic anaemia.

*Trypanosoma binneyi* is a relatively large trypanosome that commonly occurs free in the blood plasma of platypuses in Victoria and Tasmania but not in New South Wales. It is believed to be transmitted by the tick *Ixodes ornithorhynchi*. It is not known to be pathogenic.

Cysts of *Toxoplasma gondii* have been found as subclinical infections in the heart of platypuses. Unsporulated coccidial oocysts are frequently detected in faeces and the associated enteric stages in the intestinal epithelium exhibit a typical eimerian morphology and distribution without associated pathology. In addition, many platypuses have large, schizont-like bodies in vascular endothelium, adventitia and perivascular connective tissue in the intestinal lamina propria (Whittington 1988). Plerocercoids of the cestode *Spirometra erinacei* have been found in the lungs of a wild platypus, with associated parenchymal compression and focal pneumonia (Whittington *et al.* 1992).

The small intestinal flukes *Mehlisia ornithorhynchi*, *Maritrema ornithorhynchi* and *Moreauia mirabilis* have been reported from a small proportion of platypuses as subclinical infections.

All known nematodes from the platypus have been found in the skin (Whittington & Spratt 1989). Fourth-stage larval rhabditoid nematodes (?Cylindrocorporidae) were found partly embedded in the stratum corneum where they produced mild acanthosis, hyperkeratosis and inconstant subacute dermatitis. Other nematodes found include a larval trichostrongyloid nematode, an adult filaroid and *Cercopithifilaria johnstoni*.

The fleas *Pygiopsylla hopli* and *P. zethi* and two undescribed species of trombiculid mite have been observed to produce irritation of the skin, including the external ear canal (R. J. Whittington, T. R. Grant and D. M. Spratt, unpublished data).

The common platypus tick, *Ixodes ornithorhynchi*, has not been found on any other species. Burdens of larvae, nymphs and females (up to 200) are found on the less-densely haired parts of the limbs. The ticks puncture the epidermis producing dermal haemorrhage and mild, chronic, active dermatitis (Whittington & Spratt 1989). This species is believed to be the vector of the blood parasite *Theileria ornithorhynchi*.

## 7. MISCELLANEOUS CONDITIONS

Miscellaneous conditions recorded by Whittington (1988) include focal myocardial degeneration (?capture myopathy) in recently captured animals, hydropericardium, pulmonary oedema, renal tubular mineralization, cerebral infarct and appendicitis.

## 8. GENERAL DISCUSSION

Although the platypus has gained some additional habitats as a result of water conservation and management programmes in Australia, it has lost others as a result of stream degradation and drainage schemes, agriculture, urban development and road construction.

This species presumably suffered from minimal disease and traumatic events before the coming of Europeans and, indeed, many of the entities discussed in this paper occur only because of direct or indirect human activity. Recommendations as to how some of these can be prevented and/or ameliorated are given below.

1. Because platypuses apparently suffer from stress in captivity, they should not routinely be held for more

than 24 h. Prolonged captivity should only be sanctioned when there is a substantial scientific involvement by experienced workers, which is likely to lead to improved survival of individuals and/or the species. Animals exhibiting signs of significant stress at any time should be released into appropriate habitat.

- Local authorities and other bodies responsible for road maintenance should be made aware of the need to provide culverts with easy access.
- Dog owners should be made aware of the significant impact pet and working dogs have on platypus populations. Perhaps consideration can be given to providing information pamphlets with dog licences.
- Environmental awareness programmes should emphasize the danger discarded plastic litter poses to platypuses, especially those inhabiting streams in urban and rural-residential locations. An information programme similar to that for marine animal protection should be instituted.
- More research is required to elucidate the epidemiology of ulcerative mycosis of platypus.

## REFERENCES

- Collins, G. H., Whittington, R. J. & Canfield, P. J. 1986 *Theileria ornithorhynchi* Mackeras, 1959 in platypus *Ornithorhynchus anatinus* (Shaw). *J. Wildl. Dis.* **22**, 19–24.
- Connolly, J., Obendorf, D., Whittington, R. & Muir, D. 1996 Fungus festers on skin. *Microbiol. Aust.* May issue, 9.
- Frank, W., Roester, M. & Scholer, H. J. 1974 Sphaerulbildung bei einer *Mucor*—spezies in inneren organen von amphibiien. *Vorlaufige Mitteilung. Zentbl. Bakt. Parasitkde.* **226**, 405–417.
- Galloway, R. W. & Kemp, E. M. 1981 Late Cainozoic environments in Australia. In *Ecological biogeography of Australia* (ed. A. Keast), pp. 53–80. The Hague: Junk.
- Grant, T. R. 1983 Body temperatures of free ranging platypuses, *Ornithorhynchus anatinus* (Monotremata) with observations on their use of burrows. *Aust. J. Zool.* **31**, 117–122.
- McColl, K. A. 1983 Pathology in captive platypus (*Ornithorhynchus anatinus*) in Victoria, Australia. *J. Wildl. Dis.* **19**, 118–122.
- McColl, K. A. & Whittington, R. J. 1985 Leptospiral titres in wild platypuses (*Ornithorhynchus anatinus*) in New South Wales. *Aust. Vet. J.* **62**, 66.
- McDonald, I. R., Handasyde, K. A. & Evans, B. K. 1992 Adrenal function in the platypus. In *Platypus and echidnas* (ed. M. L. Augee), pp. 127–133. Sydney: The Royal Zoological Society of New South Wales.
- Manger, P. & Pettigrew, J. 1995 Electroreception and the feeding behaviour of platypus (*Ornithorhynchus anatinus*: Monotremata: Mammalia). *Phil. Trans. R. Soc. Lond. B* **347**, 359–381.
- Munday, B. L. & Peel, B. F. 1983 Severe ulcerative dermatitis in platypus (*Ornithorhynchus anatinus*). *J. Wildl. Dis.* **19**, 363–365.
- Obendorf, D. L., Peel, B. F. & Munday, B. L. 1993 *Mucor amphibiorum* infection in platypus (*Ornithorhynchus anatinus*). *J. Wildl. Dis.* **29**, 485–487.
- Richards, G. C. 1986 Predation on a platypus, *Ornithorhynchus anatinus* (Monotremata: Ornithorhynchidae) by a goshawk. *Aust. Mammal* **9**, 67.
- Slocombe, R., McCracken, H., Booth, R., Slocombe, J. & Birch, C. 1995 Infectious skin diseases of captive frogs. In *Annual Proceedings, Australian Society of Veterinary Pathology*, p. 14. Melbourne, May 1995.
- Speare, R., Thomas, A. D., O'Shea, P. O. & Shipton, W. A. 1994 *Mucor amphibiorum* in the toad, *Bufo marinus*, in Australia. *J. Wildl. Dis.* **30**, 399–407.

- Stewart, N. J. 1996 A comparison of toad- and platypus-derived cultures of *Mucor* spp. Hons. thesis, University of Tasmania.
- Tyson, R. M. 1980 Road kill platypus. *Tas. Nat.* **60**, 8.
- Whittington, R. J. 1991 The survival of platypuses in captivity. *Aust. Vet. J.* **68**, 32–35.
- Whittington, R. J. 1992 The role of infectious diseases in the population biology of monotremes. In *Platypus and echidnas* (ed. M. L. Augee), pp. 285–292. Sydney: The Royal Zoological Society of New South Wales.
- Whittington, R. J. & Grant, T. R. 1995 Haematological changes in the platypus (*Ornithorhynchus anatinus*) following capture. *J. Wildl. Dis.* **31**, 386–390.
- Whittington, R. J. & Spratt, D. M. 1989 Lesions associated with metazoan parasites of wild platypuses (*Ornithorhynchus anatinus*). *J. Wildl. Dis.* **25**, 521–526.
- Whittington, R. J., Bell, I. & Searson, J. E. 1990 A viral infection causing cytomegalic inclusion disease in the renal epithelium of the platypus (*Ornithorhynchus anatinus*). *J. Wildl. Dis.* **26**, 55–61.
- Whittington, R. J., Middleton, D., Spratt, D. M., Muntz, F., Carmel, B., McCracken, H., Struckosch, M., Stephenson-Shaw, J., Harper, P. W. & Hartley, W. J. 1992 Sparganosis in the monotremes *Tachyglossus aculeatus* and *Ornithorhynchus anatinus* in Australia. *J. Wildl. Dis.* **28**, 636–640.
- Whittington, R. W. 1988 The monotremes in health and disease. In *Australian wildlife* (ed. D. I. Bryden), pp. 727–787. Sydney: Post Graduate Foundation in Veterinary Science.
- Whittington, R. W. & McColl, K. A. 1983 Aspiration pneumonia in a wild platypus *Ornithorhynchus anatinus*. *Aust. Vet. J.* **60**, 277.



BIOLOGICAL  
SCIENCES



THE ROYAL  
SOCIETY

PHILOSOPHICAL  
TRANSACTIONS  
OF

BIOLOGICAL  
SCIENCES



THE ROYAL  
SOCIETY

PHILOSOPHICAL  
TRANSACTIONS  
OF